



# Diagnostic significance of immunological parameters in predicting the development of pneumonia in adult patients with measles

O. V. Riabokon<sup>ID</sup>\*A,E,F, S. O. Bilokobyla<sup>ID</sup>B,C,D, O. O. Korniienko<sup>ID</sup>B,E, Yu. Yu. Riabokon<sup>ID</sup>A,C,E, A. V. Vynokurova<sup>B,C</sup>

Zaporizhzhia State Medical and Pharmaceutical University, Ukraine

A – research concept and design; B – collection and/or assembly of data; C – data analysis and interpretation; D – writing the article; E – critical revision of the article; F – final approval of the article

**The aim of the study is** to determine the diagnostic significance of immunological parameters in predicting the development of pneumonia in adult patients with measles.

**Material and methods.** The study examined 88 patients aged 21 to 55 years diagnosed with measles according to the World Health Organization's criteria (2013). Enzyme-linked immunosorbent assay (ELISA) was used to determine IgG levels to the measles virus (Vircell Microbiologists, Spain) and the levels of interferon- $\gamma$  (IFN- $\gamma$ ) (Invitrogen, Austria). Statistical analysis was conducted using Statistica 13 for Windows (StatSoft Inc., No. JPZ804I382130ARCN10-J).

**Results.** According to the results of the study, it was found that upon hospitalization on the  $4.8 \pm 0.2$  day of the disease, 71.6 % of patients were seropositive for IgG to measles virus. The development of measles pneumonia was associated with the lowest level of IgG to measles virus ( $p < 0.01$ ). When the level of IgG to measles virus at hospitalization of adult patients was  $\leq 20.26$  optical units, the probability of developing measles pneumonia was significant (AUC = 0.650,  $p = 0.016$ ).

In adult patients with measles, the serum IFN- $\gamma$  level at the height of the disease was higher ( $p < 0.05$ ) than in healthy individuals. Upon hospitalization on the  $4.8 \pm 0.2$  day of the disease, the level of IFN- $\gamma$  in the setting of pneumonia was the highest ( $p < 0.05$ ), exceeding the corresponding parameter in patients without complications. The level of IFN- $\gamma$  at hospitalization  $> 1.90$  pg/ml was diagnostic for predicting the likelihood of pneumonia (AUC = 0.643,  $p = 0.038$ ).

The authors present their clinical observation, which demonstrates the informative value of using the established immunological parameters in clinical practice to predict the likelihood of pneumonia in adult patients with measles.

**Conclusions.** The diagnostic significance of such immunological parameters as IgG to measles virus and IFN- $\gamma$  in predicting the development of pneumonia in adult patients with measles at the time of hospitalization has been proved. Our clinical observation demonstrates the informativeness of the established prognostic markers.

**Keywords:** measles, viral infection, pneumonia, postvaccination antibodies, cytokines, diagnostics, prognosis.

**Current issues in pharmacy and medicine: science and practice. 2024;17(2):160-168**

## Діагностичне значення імунологічних параметрів у прогнозуванні розвитку пневмонії у хворих на кір дорослих

О. В. Рябоконт, С. О. Білокобила, О. О. Корнієнко, Ю. Ю. Рябоконт, А. В. Винокурова

**Мета роботи** – з'ясувати діагностичну значущість імунологічних параметрів у прогнозуванні розвитку пневмонії в дорослих, хворих на кір.

**Матеріали і методи.** Обстежили 88 хворих на кір віком від 21 до 55 років. Діагноз кору встановлювали за критеріями Всесвітньої організації охорони здоров'я (2013). Імуноферментним методом у сироватці крові визначали IgG до вірусу кору (Vircell Microbiologists, Spain) та рівень інтерферону- $\gamma$  (IFN- $\gamma$ ) (Invitrogen, Austria). Статистично дані опрацювали в програмі Statistica 13 for Windows (StatSoft Inc., № JPZ804I382130ARCN10-J).

**Результати.** У результаті дослідження встановили, що під час госпіталізації на  $4,8 \pm 0,2$  дня захворювання 71,6 % хворих були серопозитивними за наявності IgG до вірусу кору. Розвиток корової пневмонії асоціювався з найнижчим рівнем IgG до вірусу кору ( $p < 0,01$ ). Якщо вміст IgG до вірусу кору під час госпіталізації дорослих пацієнтів становив  $\leq 20,26$  опт. од., імовірність розвитку корової пневмонії значуща (AUC = 0,650,  $p = 0,016$ ).

### ARTICLE INFO



UDC 616.915:616.24-002]-053.8-097  
DOI: [10.14739/2409-2932.2024.2.299489](https://doi.org/10.14739/2409-2932.2024.2.299489)

**Current issues in pharmacy and medicine: science and practice. 2024;17(2):160-168**

**Keywords:** measles, viral infection, pneumonia, postvaccination antibodies, cytokines, diagnostics, prognosis.

\*E-mail: [ryabokonzsmu@ukr.net](mailto:ryabokonzsmu@ukr.net)

Received: 06.03.2024 // Revised: 18.03.2024 // Accepted: 02.04.2024

У хворих на кір дорослих вміст IFN- $\gamma$  у сироватці крові в розпал хвороби вищий ( $p < 0,05$ ), ніж у здорових осіб. Під час госпіталізації на  $4,8 \pm 0,2$  дня захворювання рівень IFN- $\gamma$  при розвитку пневмонії виявився найвищим ( $p < 0,05$ ), перевищував відповідний параметр у хворих без ускладнень. Рівень INF- $\gamma$  під час госпіталізації  $>1,90$  pg/ml мав діагностичне значення для прогнозування ймовірності розвитку пневмонії (AUC = 0,643,  $p = 0,038$ ).

Наведено власне клінічне спостереження, що демонструє інформативність застосування в клінічній практиці встановлених імунологічних параметрів для прогнозування ймовірності розвитку пневмонії у хворих на кір дорослих.

**Висновки.** Доведено діагностичну значущість таких імунологічних параметрів, як IgG до вірусу кору та IFN- $\gamma$  у прогнозуванні розвитку пневмонії у дорослих, хворих на кір, під час госпіталізації. Наведене власне клінічне спостереження підтверджує інформативність цих прогностичних маркерів.

**Ключові слова:** кір, вірусна інфекція, пневмонія, поствакцинальні антитіла, цитокіни, діагностика, прогноз.

**Актуальні питання фармацевтичної і медичної науки та практики.** 2024. Т. 17, № 2(45). С. 160-168

The introduction of measles vaccination has significantly reduced the incidence of measles [1,2], which has allowed the World Health Organization to set the goal of eliminating measles in the European region [3]. On one hand, increased measles immunization has substantially decreased morbidity and mortality from this infection. On the other hand, the epidemiology of measles in countries with high immunization rates has undergone significant changes [4]. In recent decades, measles has ceased to be solely a childhood infection [4]. Countries with high levels of vaccination and revaccination among children have observed a decline in post-vaccination measles IgG levels in adults. However, the consequences of this phenomenon during the period of measles elimination remain insufficiently understood [5].

In 2017–2018, many countries worldwide experienced an epidemiological deterioration in measles [6,7,8,9,10,11,12]. A notable feature of the recent measles epidemic was the significant prevalence of adult cases. For instance, in Germany, adults constituted 52 % of measles cases [8], in Italy – 73 % [10], and in Belgium – 50 % [11]. This trend was also observed in Asian countries; for example, in Sri Lanka, the proportion of adult patients with measles reached 73.3 % [12].

It is recognized that measles in adults poses a higher risk of complications compared to children [6,13,14]. The most common complication believed to occur is measles pneumonia, although literature reports on its frequency vary considerably [14]. Thus, there is a current need to ascertain the incidence of pneumonia in adult patients with measles.

Understanding the development of measles pneumonia involves not only viral replication but also immunopathogenetic mechanisms, which are still under investigation. The measles virus initially infects alveolar macrophages and dendritic cells in the respiratory tract, then replicates in local lymphatic tissue, and disseminates through viremia [15]. The immunopathogenetic features of measles complications involve the “measles paradox” – the progression of measles with severe immunosuppression even before acute viremia signs disappear [16,17]. On one hand, complications arise from immunosuppression due to viremia progression, while on the other hand, measles virus replication induces lifelong anti-measles immunity [18]. Since the cytokine system governs the functional activity of immune cells, and impaired production of anti-inflammatory cytokines may contribute to direct viral damage to organs and systems [19], assessing

the diagnostic significance of immunological parameters is advisable for predicting measles in adults.

### Aim

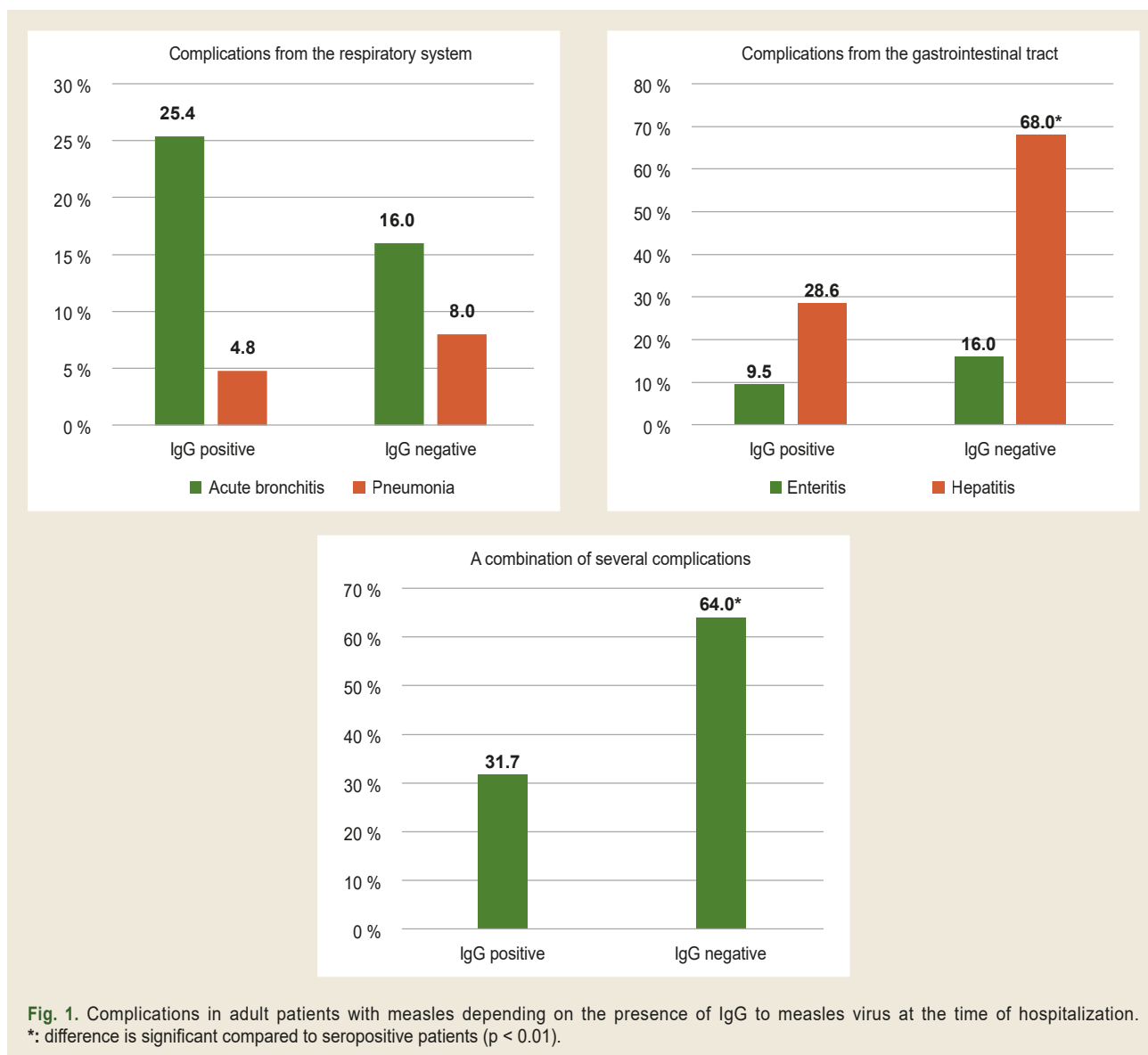
The aim of the study is to determine the diagnostic significance of immunological parameters in predicting the development of pneumonia in adult patients with measles.

### Material and methods

The study included 88 patients with measles aged 21 to 55 years who were treated at the Municipal non-profit enterprise “Regional Infectious Diseases Clinical Hospital” of the Zaporizhzhia regional council during 2017–2019. There were 36 men and 52 women. All patients were included in the study on a random basis and with informed consent. The diagnosis of measles was made according to the criteria of the World Health Organization (2013). In the anamnesis, all patients with measles indicated the presence of measles vaccination in childhood, but there was no documentary evidence.

To determine the presence of probable post-vaccination antibodies during hospitalization, serum IgG to measles virus was determined (Vircell Microbiologists, Spain). The serum levels of interferon- $\gamma$  (IFN- $\gamma$ ) were determined in patients and 20 healthy subjects (Invitrogen, Austria). The studies were conducted by enzyme-linked immunosorbent assay at the Training Medical and Laboratory Center of Zaporizhzhia State Medical and Pharmaceutical University (Head – Doctor of Pharmacy, Associate Professor R. O. Shcherbyna).

Statistical processing of the data was performed using the software Statistica 13 for Windows (StatSoft Inc., No. JPZ804I382130ARCN10-J). The results of quantitative data were presented as median and interquartile ranges Me [Q25; Q75]. The Mann–Whitney test was used to assess the reliability of differences between quantitative characteristics in independent groups, Wilcoxon test in dependent groups, and the  $\chi^2$  method for qualitative characteristics. Correlations between quantitative features were determined using Spearman’s correlation ( $r$ ). ROC analysis was performed to determine the diagnostic significance of the content of IgG to the measles virus and IFN- $\gamma$  level in predicting the development of pneumonia. Differences at  $p < 0.05$  were considered significant.



## Results

According to the results of the study, it was found that during the hospitalization of adult patients on an average of  $4.8 \pm 0.2$  days of illness, 63 (71.6 %) patients were seropositive for the presence of IgG to measles virus, and the remaining 25 (28.4 %) were seronegative. Analysis of the spectrum and frequency of complications in adult patients with measles depending on the presence of IgG to measles virus revealed that the incidence of pneumonia has a clear tendency to increase in the setting of seronegativity (1.7 times,  $p > 0.05$ ). However, the incidence of gastrointestinal complications in adult patients with measles was significantly higher in seronegative patients (2.3 times,  $\chi^2 = 10.60$ ,  $p < 0.001$ ), with this pattern also applying to the development of hepatitis (2.4 times,  $\chi^2 = 11.61$ ,  $p < 0.001$ ). It should also be noted that in seronegative patients, in contrast to seropositive patients with IgG to measles virus on  $4.8 \pm 0.2$  day of illness, a combination of several complications was significantly more frequent (2 times,  $\chi^2 = 7.70$ ,  $p < 0.01$ ) (Fig. 1).

To further investigate the protective role of probably postvaccination antibodies in adult measles patients in the development of pneumonia, we compared their quantitative content at the time of hospitalization depending on the further development of pneumonia. Among the seropositive patients, the lowest level of IgG to measles virus occurred in patients with the development of measles pneumonia and was 16.80 [14.68; 20.26] units against 23.58 [21.87; 26.78] optical units in patients without complications ( $p = 0.0002$ ). According to the results of the ROC-analysis, the diagnostic value of this parameter on  $4.8 \pm 0.2$  day of illness was established for predicting the development of pneumonia. For instance, when the content of IgG to measles virus during hospitalization of adult patients was  $\leq 20.26$  optical units (AUC = 0.650; sensitivity – 92.3 %, specificity – 52.0 %), the probability of developing measles pneumonia was significant ( $p = 0.016$ ) (Fig. 2).

In the next part of the work, we compared the level of IFN- $\gamma$  in the blood serum of adult patients with measles in the dynamics

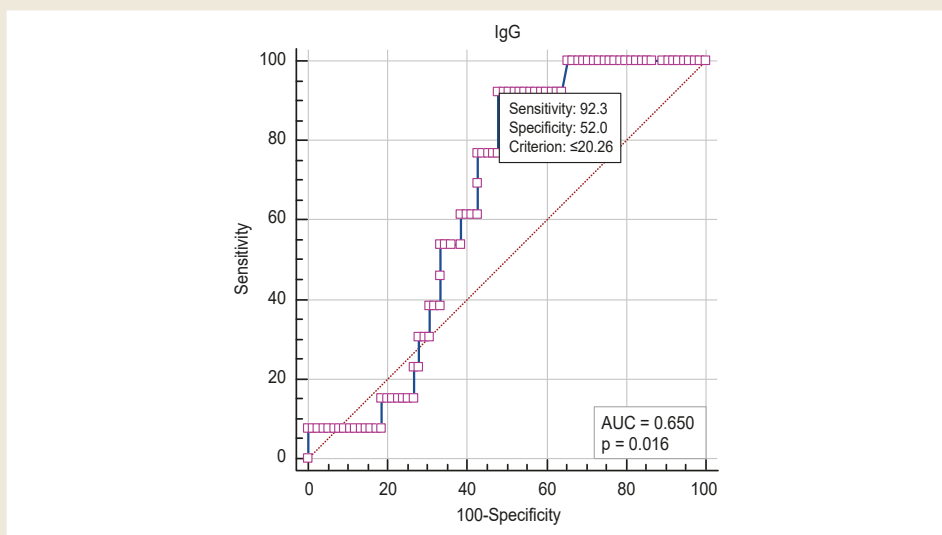


Fig. 2. Prediction of the probability of out-of-hospital pneumonia based on the level of IgG to measles virus in adult patients during hospitalization.

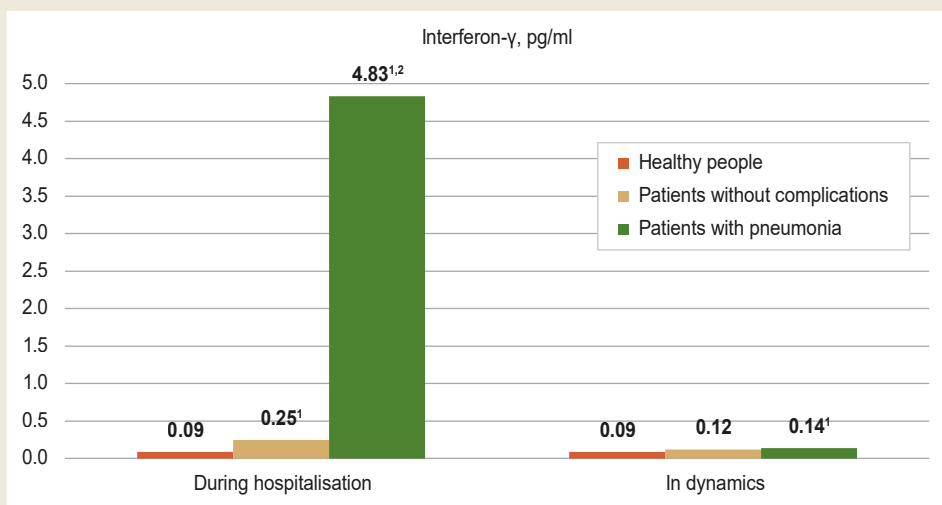


Fig. 3. Comparison of serum IFN- $\gamma$  levels in adult patients with measles in the dynamics of the disease depending on the development of pneumonia. 1: the difference is significant compared to healthy people ( $p < 0.05$ ); 2: compared to patients without complications ( $p < 0.05$ ).

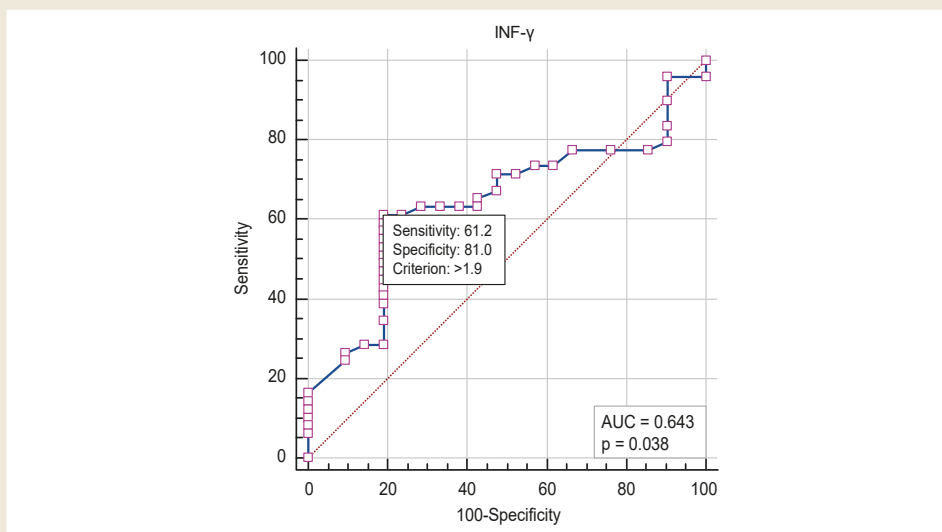


Fig. 4. The likelihood of pneumonia development prediction by the level of INF- $\gamma$  in the blood serum of adult patients at hospital admission.

of the disease depending on the development of pneumonia. The level of IFN- $\gamma$  during hospitalization was higher than in healthy people, regardless of the development of pneumonia ( $p < 0.05$ ). It should be noted that in the setting of pneumonia, the level of IFN- $\gamma$  was the highest and significantly higher than in healthy people and patients with measles without complications, namely, 4.83 [0.29; 12.86] pg/ml as compared to 0.09 [0.08; 0.20] pg/ml and 0.25 [0.13; 1.14] pg/ml, respectively. In the dynamics of 7–10 days of treatment in patients without complications, the level of IFN- $\gamma$  in the serum of adult patients with measles normalised ( $p > 0.05$ ) and amounted to 0.12 [0.08; 0.24] pg/ml, in contrast to the level of IFN- $\gamma$  in patients with pneumonia, which was 0.14 [0.08; 0.58] pg/ml and remained higher compared to healthy people ( $p < 0.05$ ) (Fig. 3).

According to the results of ROC analysis, the cut-off level of increase in serum INF- $\gamma$ , which is diagnostic for predicting the development of pneumonia, was determined. It was found that with an increase in the level of INF- $\gamma > 1.90$  pg/ml, the probability of developing pneumonia is significant (AUC = 0.643,  $p = 0.038$ ; sensitivity – 61.2 %, specificity – 81.0 %) (Fig. 4).

The correlations of the studied immunological parameters with laboratory parameters were established, which indicate both the severity of the disease and the formation of complications. The level of IgG to the measles virus in the blood serum correlated with the following parameters: platelets ( $r = +0.32$ ,  $p < 0.05$ ), lymphocytes ( $r = +0.46$ ,  $p < 0.05$ ), alanine aminotransferase activity ( $r = -0.45$ ,  $p < 0.05$ ), and rods cells ( $r = -0.36$ ,  $p < 0.05$ ). The level of INF- $\gamma$  correlated with the level of rods ( $r = 0.38$ ,  $p < 0.001$ ), segmented leukocytes ( $r = -0.32$ ,  $p < 0.01$ ), lymphocytes ( $r = 0.31$ ,  $p < 0.01$ ), and alanine aminotransferase activity ( $r = 0.25$ ,  $p < 0.05$ ).

In the following part of the paper, we present a clinical case that, in our opinion, allows us to demonstrate the features of the development of measles pneumonia in an adult patient and demonstrate the possibility of using the immunological parameters studied to predict the development of pneumonia.

**Clinical case.** Patient T., 55 years old, was admitted to the Municipal non-profit enterprise “Regional Infectious Diseases Clinical Hospital” of the Zaporizhzhia regional council on 10.01.2019 (on the 7<sup>th</sup> day of illness) with complaints of fever up to 39.5 °C, severe weakness, shortness of breath at rest, a profuse skin rash, dry hacking cough with pain behind the sternum, and decreased appetite.

From the medical history, it became known that he fell ill on 04.01.2019 with hyperthermia of 40.0 °C, eye pain, dry cough. He took antipyretic drugs on his own, but against the background of persistent fever on 08.01.2019, shortness of breath appeared, on the 6<sup>th</sup> day of illness a rash on the skin of the face and swelling of the face appeared, on the 7<sup>th</sup> day of illness a rash on the skin of the trunk and arms appeared, shortness of breath increased. The patient sought medical attention and was hospitalized.

In the history of life: has chronic obstructive pulmonary disease, grade II obesity (body mass index 36.1 kg/m<sup>2</sup>), type 2 diabetes mellitus. There is no documentary evidence of previous vaccinations.

Epidemiological history: contact with a son who had measles and had laboratory confirmation of measles diagnosis.

On admission, the patient’s condition was critical due to severe signs of intoxication and acute respiratory failure. Body temperature 39.0 °C, tachycardia 112/min, blood pressure 130/70 mmHg, dyspnoea up to 44/min, oxygen saturation 86 % (with the connection of oxygen therapy in mask mode, oxygen saturation was 96 %, dyspnoea decreased to 28/min). The patient was admitted to the intensive care unit for treatment. Consciousness was clear, scleritis and conjunctivitis were pronounced, the face was swollen, and the skin of the face, trunk, and extremities had a bright, plentiful, confluent spotted-papular rash, which in some places had a hemorrhagic component. Oral mucosa with enanthema, positive Filatov–Koplik symptom. Auscultation of breath sounds over the lungs was decreased in the lower parts on both sides, crepitation was heard on the right.

Based on the clinical and anamnestic data during the initial examination of the patient, the diagnosis was made: measles (epidemiologically linked case), rash period, severe course, complicated by out-of-hospital pneumonia.

X-ray examination of 10.01.2019 on the right revealed lung tissue infiltration in the middle lobe projection, which confirmed the development of right-sided middle lobe pneumonia (Fig. 5A).

When interpreting the results of laboratory tests in the general blood analysis, the presence of neutrophilia up to 85 % with an increase in rod-nuclear leukocytes up to 14 %, lymphopenia up to 13 % (abs.  $0.78 \times 10^9/l$ ), thrombocytopenia up to  $138 \times 10^9/l$ , the appearance of plasma cells up to 3 %, acceleration of erythrocyte sedimentation rate up to 50 mm/h. In the biochemical indicators, there were signs of hypercoagulation with an increase in the levels of the prothrombin index to 107.7 % and fibrinogen to 5.1 g/l; signs of acute kidney damage, namely an increase in urea to 8.2 mmol/l, creatinine to 130.0  $\mu\text{mol/l}$ , proteinuria 0.264 g/l; as well as hyperglycemia up to 14.3 mmol/l.

Taking into account weakly positive meningeal symptoms, namely stiffness of the occipital muscles and Kernig’s symptom, a lumbar puncture was performed for diagnostic purposes. In the cerebrospinal fluid, cytosis was 1 cell per mcl, lymphocyte, protein 0.09 g/l, which made it possible to rule out the presence of meningitis.

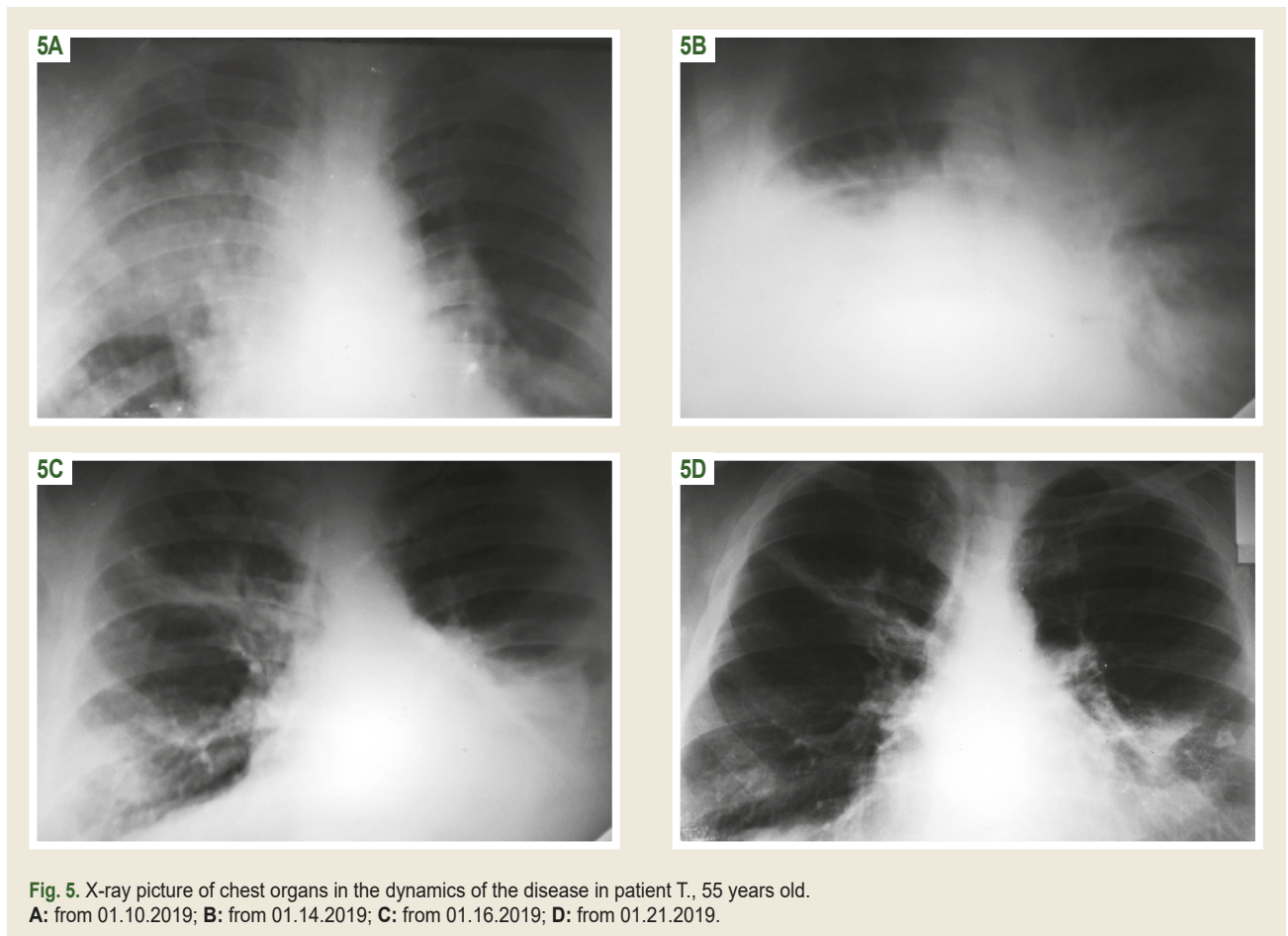
According to the analysis of the patient’s immunological parameters, which we studied, it was established that at the time of hospitalization, the content of IgG to the measles virus was  $\leq 20.26$  opt. units, and the level of IFN- $\gamma > 1.82$  pg/ml, which indicated a high probability of developing pneumonia (Table 1).

The treatment was prescribed: oxygen therapy in a mask mode, infusion therapy in the volume of 400.0 ml, antibacterial therapy with ceftriaxone in a dose of 2.0 g twice a day intravenously, low molecular weight heparin in a prophylactic dose of enoxaparin 4000 anti-Xa MO/0.4 ml subcutaneously once per day, ambroxol orally, antipyretic drugs according to indications.



**Table 1.** The level of IgG to the measles virus and IFN- $\gamma$  in the blood serum of measles patient T., 55 years old at the time of hospitalization

Indicator, units of measurement	Prediction according to ROC analysis	Patient T., 55 years old
IgG to the measles virus, opt. unit	$\leq 20.26$	16.64
IFN- $\gamma$ , pg/ml	$> 1.9$	12.86



Despite the prescribed treatment, clinical signs of acute respiratory failure persisted during the initial five days, characterized by a respiratory rate of 28–30 breaths per minute and oxygen saturation of 90 % without supplemental oxygen, which increased to 96–97 % with oxygen support. Additionally, there was a persistent low-grade fever, and auscultation of the lungs revealed negative dynamics, including weakening of breath sounds in the lower lung fields and the presence of crepitation bilaterally. Radiologically, beginning on January 14, 2019, there was evidence of increasing infiltration of lung tissue: on the right side, affecting the middle and lower lobes, and on the left side, affecting both lobes, with the roots of the lungs appearing compacted and structureless. Sinuses and mediastinal organs were not visualized. The radiographic findings were consistent with a diagnosis of bilateral polysegmental pneumonia (*Fig. 5B*).

During the laboratory examination on 01.13.2019 negative dynamics were also noted in the general blood analysis due to an increase in the expression of neutrophilia to 80 %, rod-nuclear shift to 21 %, expression of lymphopenia to 6 % (abs.

$0.49 \times 10^9/l$ ), thrombocytopenia  $145 \times 10^9/l$ , preservation of plasma cells up to 2 %.

Correction of treatment was carried out on 01.14.2019: combined antibacterial therapy with levofloxacin 500 mg twice a day intravenously and ceftriaxone at a dose of 2.0 g twice a day intravenously, glucocorticosteroids at a dose of 2 mg/kg of body weight under prednisone was prescribed (within three days), an infusion of 10 % immunoglobulin for intravenous administration in a dose of 200.0 ml once was prescribed.

After correction of treatment during 01.14.2019–01.16.2019 clear positive dynamics were obtained: steady normalization of body temperature, since 16.01.2019 oxygen dependence disappeared, oxygen saturation 95–96 % without oxygen support, frequency of respiratory movements 22–24/min, auscultation reduced crepitus, rash on the skin became significantly less bright. From 01.17.2019 the patient was transferred to the department for further treatment.

Research results also clearly demonstrated positive dynamics. Thus, according to the results of an X-ray examination

of the chest organs from 01.16.2019, a decrease in lung tissue infiltration was noted in all parts of the lungs. Conclusion: left-sided lower lobe and right-sided middle lobe and lower lobe pneumonia (*Fig. 5C*).

During the laboratory examination in the general blood test on 01.15.2019, clear positive dynamics were noted due to a significant decrease in the rod-nuclear shift to the left to 7 %, an increase in the level of the relative and absolute number of lymphocytes to 20 % (abs.  $0.76 \times 10^9/l$ ), platelets to  $168 \times 10^9/l$ . In biochemical indicators, there are no deviations from the reference values.

Against the background of further treatment, clear positive dynamics of clinical, laboratory, and X-ray data remained. During the control X-ray examination on 01.21.2019, a further decrease in lung tissue infiltration was noted, such as signs of infiltration remaining on the left in the lower lobe and on the right in the middle lobe (*Fig. 5D*). The patient was discharged with recommendations for continued treatment in outpatient settings.

As can be seen from the given clinical example, a 55-year-old patient had a severe course of measles, which was complicated by the development of pneumonia. During hospitalization, the results of immunological studies, namely the level of IgG antibodies to the measles virus, were 16.64 opt. unit and an IFN- $\gamma$  level of 12.86 pg/ml indicated a high risk of developing measles pneumonia. The development and progression of pneumonia during the first five days were characterized by an increase in infiltrative changes in the lung tissue according to X-ray examination data, the appearance of signs of acute respiratory failure of the first degree, inflammatory changes in the general blood test with the presence of a rod-shaped nucleus shift to the left, the appearance of plasma cells, the appearance of signs of hypercoagulation. These changes required the appointment of combined antibacterial therapy, the use of corticosteroids, and anticoagulant therapy.

## Discussion

In modern conditions, almost all studies demonstrate the dependence of the frequency of measles complications on the age of patients. It should be noted that the main age groups at risk for a complicated course of measles are children in the first year of life and adults [6,11]. One of the most serious complications of measles is out-of-hospital pneumonia, however, literature data on the frequency of this complication vary significantly [11,20,21]. Thus, under conditions of sporadic measles incidence among adults, a high rate of development of this complication was noted, namely 57 % [14]. During the growth of the morbidity rate, according to various authors, the frequency of pneumonia among hospitalized patients was 15.3–20.6 % [22]. The severity of the course of measles pneumonia in adult patients was demonstrated in the study [23], namely, it was proven that measles was complicated by out-of-hospital pneumonia in 31 % of patients, of which 72 % of patients required oxygen support. During the last epidemic rise in the incidence of measles in Ukraine among military personnel, the development of pneumonia occurred in every fifth patient, despite the mild course of measles [13].

According to the results of our study, among hospitalized adult measles patients, the frequency of pneumonia was 5.7 %. Today, significant differences in the assessment of the frequency of pneumonia in adult measles patients are explained by the use of different imaging methods for its confirmation. The researchers draw attention to the fact that pneumonia in measles patients was suspected in the presence of a weakening of breathing in the lower parts of the lungs in the absence of wheezing, and its confirmation in most cases required not an X-ray examination, but a computer tomography [11]. In our study, only radiographic examination was used to confirm pneumonia, which to some extent may explain the low frequency of this complication in adult measles patients even during the epidemic rise in measles incidence.

In our study, the role of probably post-vaccination IgG to the measles virus in the development of such a complication as pneumonia in adults was determined. Today, the presented literature draws attention to the possibility of developing pneumonia in adults who were previously vaccinated against measles [24,25,26].

Elucidation of the pathogenetic mechanisms of the development of pneumonia in previously vaccinated adults against measles continues [27]. The appearance of foci of inflammation in the lungs is explained by the development of a type III hypersensitivity reaction, when in the process of replication of the measles virus in previously vaccinated patients, rapid production of IgG against the measles virus occurs, a significant number of immune complexes are formed, and foci of inflammation appear in the lungs, which have an immune complex mechanism of development [28]. It is assumed that the immunopathogenetic mechanism of the development of focal measles pneumonia in vaccinated individuals may differ from the mechanism of its development in non-vaccinated individuals [24]. In a number of studies, it has been demonstrated that foci of measles pneumonia in previously vaccinated individuals appear in the acute period of the disease, but subsequently regress for a very long time, from 2 months [26] to 8 months [25]. In addition, primarily in previously vaccinated individuals, measles pneumonia is most often focal and is diagnosed not by radiographic examination, but by computer tomography [24,25,26].

When analyzing modern literature, we paid attention to the attempt of researchers [24] to propose serological prognostic criteria for the development of pneumonia in previously vaccinated individuals. Namely, a ratio of IgG/IgM  $>20$  was proposed, which may be useful for the diagnosis of measles pneumonia [24]. In our study, we managed to establish a cut-off level of IgG to the measles virus  $\leq 20.26$  opt. units, which gives an idea of the probability of developing measles pneumonia.

Various links to the immunopathological mechanisms of the formation of measles pneumonia continue to be studied today. During the development of measles pneumonia, the inflammatory process is characterized as serous-macrophagic, accompanied by lymphocytic infiltration and vasculitis of small vessels [29].

It is known that IFN- $\gamma$  is one of the key cytokines responsible for the formation of the Th1 type of immune response

and is involved in the development of systemic and local inflammatory and immunopathological reactions, which causes the appearance of a rash and the clearance of the measles virus [30]. However, the acute phase of measles has a significant feature and differs from the classic reaction, as it is characterized by the formation of leukopenia in combination with a high level of IFN- $\gamma$  [31,32]. In our study, we established the highest level of IFN- $\gamma$  under the conditions of the development of measles pneumonia and found out the cut-off level of this cytokine, which allows us to state the probability of the development of this complication in adult measles patients.

## Conclusions

1. When hospitalized on the  $4.8 \pm 0.2$  day of illness, 71.6 % of patients are seropositive for the presence of IgG to the measles virus. The development of measles pneumonia is associated with the lowest level of IgG to the measles virus ( $p < 0.01$ ). Under the conditions of IgG content to the measles virus during hospitalization of adult patients  $\leq 20.26$  opt. units, the probability of developing measles pneumonia is significant ( $AUC = 0.650$ ,  $p = 0.016$ ).

2. In adults with measles, the content of IFN- $\gamma$  in blood serum at the height of the disease is higher ( $p < 0.05$ ) than in healthy individuals. During hospitalization on the  $4.8 \pm 0.2$  day of the disease, the level of IFN- $\gamma$  under the conditions of the development of pneumonia is the highest ( $p < 0.05$ ), exceeding the corresponding parameter in patients without complications. The level of INF- $\gamma$  during hospitalization  $> 1.90$  pg/ml has a diagnostic value for predicting the probability of developing pneumonia ( $AUC = 0.643$ ;  $p = 0.038$ ).

3. The given clinical case demonstrates the informativeness of the application in clinical practice of the immunological parameters established for predicting the probability of developing pneumonia in adult measles patients.

**Prospects for further research.** In our opinion, taking into account the strategy of the World Health Organization regarding the elimination of measles in the European region, today it remains relevant to clarify the peculiarities of immunological parameters, in particular cellular immunity, in predicting the course of measles in adults.

**Conflicts of interest:** authors have no conflict of interest to declare.  
**Конфлікт інтересів:** відсутній.

### Information about the authors:

Riabokon O. V., MD, PhD, DSc, Professor, Head of the Department of Infectious Diseases, Zaporizhzhia State Medical and Pharmaceutical University, Ukraine.

ORCID ID: 0000-0002-7394-4649

Bilokobyla S. O., MD, PhD, Assistant of the Department of Infectious Diseases, Zaporizhzhia State Medical and Pharmaceutical University, Ukraine.

ORCID ID: 0000-0002-5673-616X

Korniienko O. O., MD, PhD, Associate Professor of the Department of Infectious Diseases, Zaporizhzhia State Medical and Pharmaceutical University, Ukraine.

ORCID ID: 0000-0002-5196-7698

Riabokon Yu. Yu., MD, PhD, DSc, Professor of the Department of Children Infectious Diseases, Zaporizhzhia State Medical and Pharmaceutical University, Ukraine.

ORCID ID: 0000-0002-2273-8511

Vynokurova A. V., Leading Specialist of Educational and Scientific Medical Laboratory Center with a vivarium, Zaporizhzhia State Medical and Pharmaceutical University, Ukraine.

### Відомості про авторів:

Рябокoнь О. В., д-р мед. наук, професор, зав. каф. інфекційних хвороб, Запорізький державний медико-фармацевтичний університет, Україна.

Білокобила С. О., PhD, асистентка каф. інфекційних хвороб, Запорізький державний медико-фармацевтичний університет, Україна.

Корнієнко О. О., канд. мед. наук, доцент каф. інфекційних хвороб, Запорізький державний медико-фармацевтичний університет, Україна.

Рябокoнь Ю. Ю., д-р мед. наук, професор каф. дитячих інфекційних хвороб, Запорізький державний медико-фармацевтичний університет, Україна.

Винокурова А. В., провідний фахівець Навчально-наукового медико-лабораторного центру з віварієм, Запорізький державний медико-фармацевтичний університет, Україна.

### References

- Gastañaduy PA, Funk S, Lopman BA, Rota PA, Gambhir M, Grenfell B, et al. Factors Associated With Measles Transmission in the United States During the Postelimination Era. *JAMA Pediatr.* 2020;174(1):56-62. doi: [10.1001/jamapediatrics.2019.4357](https://doi.org/10.1001/jamapediatrics.2019.4357)
- Plans-Rubió P. Are the Objectives Proposed by the WHO for Routine Measles Vaccination Coverage and Population Measles Immunity Sufficient to Achieve Measles Elimination from Europe? *Vaccines (Basel)*. 2020;8(2):218. doi: [10.3390/vaccines8020218](https://doi.org/10.3390/vaccines8020218)
- Gastañaduy PA, Goodson JL, Panagiotakopoulos L, Rota PA, Orenstein WA, Patel M. Measles in the 21st Century: Progress Toward Achieving and Sustaining Elimination. *J Infect Dis.* 2021;224(12 Suppl 2):S420-8. doi: [10.1093/infdis/jjaa793](https://doi.org/10.1093/infdis/jjaa793)
- Hayman DT. Measles vaccination in an increasingly immunized and developed world. *Hum Vaccin Immunother.* 2019;15(1):28-33. doi: [10.1080/21645515.2018.1517074](https://doi.org/10.1080/21645515.2018.1517074)
- Gidding HF, Quinn HE, Hueston L, Dwyer DE, McIntyre PB. Declining measles antibodies in the era of elimination: Australia's experience. *Vaccine.* 2018;36(4):507-13. doi: [10.1016/j.vaccine.2017.12.002](https://doi.org/10.1016/j.vaccine.2017.12.002)
- Kramarov S, Yevtushenko V, Kovalyukh I, Kaminska T, Golovach O. [Clinical features of measles in children hospitalized during 2017-2018 outbreak]. *Aktualna infektologhiia.* 2018;6(5):240-5. Ukrainian. doi: [10.22141/2312-413x.6.5.2018.146773](https://doi.org/10.22141/2312-413x.6.5.2018.146773)
- Georgakopoulou T, Horefti E, Vernardaki A, Pogka V, Gkolfinopoulou K, Triantafyllou E, et al. Ongoing measles outbreak in Greece related to the recent European-wide epidemic. *Epidemiol Infect.* 2018;146(13):1692-8. doi: [10.1017/S0950268818002170](https://doi.org/10.1017/S0950268818002170)
- Saffar H, Khalifelloo M, Saffar MJ, Abdollahi A, Parsaei MR, Ghorbani GR, et al. Measles and rubella serosusceptibility among population vaccinated with different schedules: the potential impact on measles-rubella elimination in Iran. *BMC Infect Dis.* 2021;21(1):305. doi: [10.1186/s12879-021-05970-7](https://doi.org/10.1186/s12879-021-05970-7)
- Werber D, Hoffmann A, Santibanez S, Mankertz A, Sagebiel D. Large measles outbreak introduced by asylum seekers and spread among the insufficiently vaccinated resident population, Berlin, October 2014 to August 2015. *Euro Surveill.* 2017;22(34):30599. doi: [10.2807/1560-7917.ES.2017.22.34.30599](https://doi.org/10.2807/1560-7917.ES.2017.22.34.30599)
- Lancella L, Di Camillo C, Vittucci AC, Boccuzzi E, Bozzola E, Villani A. Measles lessons in an anti-vaccination era: public health is a social duty, not a political option. *Ital J Pediatr.* 2017;43(1):102. doi: [10.1186/s13052-017-0420-6](https://doi.org/10.1186/s13052-017-0420-6)
- Gammens T, Schirvel C, Leenen S, Shodu N, Hutse V, Mendes da Costa E, et al. Ongoing measles outbreak in Wallonia, Belgium, December 2016 to March 2017: characteristics and challenges. *Euro Surveill.* 2017;22(17):30524. doi: [10.2807/1560-7917.ES.2017.22.17.30524](https://doi.org/10.2807/1560-7917.ES.2017.22.17.30524)
- Dahanayaka NJ, Pahalagamage S, Ganegama RM, Weerawansa P, Agampodi SB. The 2013 measles outbreak in Sri Lanka: experience from a rural district and implications for measles elimination goals. *Infect Dis Poverty.* 2015;4:51. doi: [10.1186/s40249-015-0084-7](https://doi.org/10.1186/s40249-015-0084-7)



13. Trykhlіb V, Shchur A, Hrushkevych V, Hryshyn O, Pavlovska M, Musiienko T, et al. [Peculiarities of measles clinical manifestations and course]. *Aktualna infektolohiia*. 2018;6(3):141-52. Ukrainian. doi: [10.22141/2312-413x.6.3.2018.136647](https://doi.org/10.22141/2312-413x.6.3.2018.136647)
14. Premaratna R, Luke N, Perera H, Gunathilake M, Amarasena P, Chandrasena TG. Sporadic cases of adult measles: a research article. *BMC Res Notes*. 2017;10(1):38. doi: [10.1186/s13104-017-2374-6](https://doi.org/10.1186/s13104-017-2374-6)
15. de Vries RD, Mesman AW, Geijtenbeek TB, Duprex WP, de Swart RL. The pathogenesis of measles. *Curr Opin Virol*. 2012;2(3):248-55. doi: [10.1016/j.coviro.2012.03.005](https://doi.org/10.1016/j.coviro.2012.03.005)
16. Anelone AJ, Hancock EJ, Klein N, Kim P, Spurgeon SK. Control theory helps to resolve the measles paradox. *R Soc Open Sci*. 2021;8(4):201891. doi: [10.1098/rsos.201891](https://doi.org/10.1098/rsos.201891)
17. Morris SE, Yates AJ, de Swart RL, de Vries RD, Mina MJ, Nelson AN, et al. Modeling the measles paradox reveals the importance of cellular immunity in regulating viral clearance. *PLoS Pathog*. 2018;14(12):e1007493. doi: [10.1371/journal.ppat.1007493](https://doi.org/10.1371/journal.ppat.1007493)
18. Laksono BM, de Vries RD, McQuaid S, Duprex WP, de Swart RL. Measles Virus Host Invasion and Pathogenesis. *Viruses*. 2016;8(8):210. doi: [10.3390/v8080210](https://doi.org/10.3390/v8080210)
19. Andreychyn MA, Vasylieva NA, Yosyk YI. [Role of interleukins in pathogenesis of influenza and other acute respiratory viral infections]. *Zhurnal Natsionalnoi akademii medychnykh nauk Ukrainy*. 2015;21(1):122-7. Ukrainian.
20. Ge YL, Zhai XW, Zhu YF, Wang XS, Xia AM, Li YF, et al. Measles Outbreak in Pediatric Hematology and Oncology Patients in Shanghai, 2015. *Chin Med J (Engl)*. 2017;130(11):1320-6. doi: [10.4103/0366-6999.206358](https://doi.org/10.4103/0366-6999.206358)
21. Xu ZW, Chen YP, Yang MJ, Li WC, Liu Q, Lin J. The epidemiological and clinical characteristics of measles in Wenzhou, China, 2000-2010. *Epidemiol Infect*. 2014;142(1):20-7. doi: [10.1017/S0950268813000411](https://doi.org/10.1017/S0950268813000411)
22. Antona D, Lévy-Bruhl D, Baudon C, Freymuth F, Lamy M, Maine C, et al. Measles elimination efforts and 2008-2011 outbreak, France. *Emerg Infect Dis*. 2013;19(3):357-64. doi: [10.3201/eid1903.121360](https://doi.org/10.3201/eid1903.121360)
23. Caseris M, Houhou N, Longuet P, Rioux C, Lepeule R, Choquet C, et al. French 2010-2011 measles outbreak in adults: report from a Parisian teaching hospital. *Clin Microbiol Infect*. 2014;20(4):O242-4. doi: [10.1111/1469-0691.12384](https://doi.org/10.1111/1469-0691.12384)
24. Yu D, Zhang G, Gao L, Xu W, Cao B. High ratio of measles-specific IgG/IgM associated with nodular pneumonia in vaccinated individuals. *Int J Infect Dis*. 2018;76:38-44. doi: [10.1016/j.ijid.2018.08.015](https://doi.org/10.1016/j.ijid.2018.08.015)
25. Ohnishi H, Fujiyama R, Tomioka H, Tada K, Sakurai T, Sakamoto H, et al. [Measles pneumonia presenting with multiple nodular opacities on chest radiographs]. *Nihon Kokyuki Gakkai Zasshi*. 2000;38(5):421-4. Japanese.
26. Pang M, Xu JY, Li P, Han XX, Li MY. [Clinical analysis of 51 cases of atypical measles syndrome characterized by fever and multiple lung lesions]. *Zhonghua Jie He He Hu Xi Za Zhi*. 2008;31(10):731-5. Chinese.
27. Moss WJ. Measles. *Lancet*. 2017;390(10111):2490-502. doi: [10.1016/S0140-6736\(17\)31463-0](https://doi.org/10.1016/S0140-6736(17)31463-0)
28. Melenotte C, Cassir N, Tessonnier L, Brouqui P. Atypical measles syndrome in adults: still around. *BMJ Case Rep*. 2015;2015:bcr2015211054. doi: [10.1136/bcr-2015-211054](https://doi.org/10.1136/bcr-2015-211054)
29. Shostakovych-Koretsraya LR, Mavrutenkov VV, Cherhinet AV, Budyayeva IV, Yakunina OM, Chykarenko ZA. Measles (lecture). *Medicini perspektivi*. 2013;18(3):4-15. Ukrainian.
30. Griffin DE. Measles virus-induced suppression of immune responses. *Immunol Rev*. 2010;236:176-89. doi: [10.1111/j.1600-065X.2010.00925.x](https://doi.org/10.1111/j.1600-065X.2010.00925.x)
31. Ten Oever J, Riza A, Sabou M, Cismaru C, Netea MG, Slavcovici A. Characterization of the Acute Inflammatory Response in Measles Infection. *J Pediatric Infect Dis Soc*. 2014;3(3):197-200. doi: [10.1093/jpids/pit082](https://doi.org/10.1093/jpids/pit082)
32. Veklych KA, Popov MM, Liadova TI, Martynenko OV, Sorokina OH, Sarkis-Ivanova VV. [Cytokine profile of patients with the measles infection of varying severity]. *Pathologia*. 2021;18(1):66-71. Ukrainian. doi: [10.14739/2310-1237.2021.1.215491](https://doi.org/10.14739/2310-1237.2021.1.215491)