



Morphological rearrangement of the metabolic link of the microcirculatory bed of guinea pigs lungs after sensitization with ovalbumin

S. S. Popko 

Zaporizhzhia State Medical University, Ukraine

The reaction of the lung microvessels is an urgent issue of morphology and medicine in general, as well as one of the insufficiently investigated points in the study of morphological changes in chronic allergic diseases of the respiratory system.

The aim is to study the morphological changes in the vessels of the metabolic link of the microcirculation in the lungs of guinea pigs sensitized with ovalbumin.

Materials and methods. We have studied the lungs of 48 guinea pigs, using histological and morphometric methods, under conditions of experimental ovalbumin-induced allergic inflammation, simulated by three-time subcutaneous sensitization and subsequent 8-day intranasal inhalation of ovalbumin. To estimate the structural and functional state of capillaries, the inner diameter of the vessels was determined.

Results. A general regularity in the reactivity of the hemomicrocirculatory bed of guinea pig lungs in experimental ovalbumin-induced allergic inflammation was established, which consists in a significant structural and functional restructuring of the exchange vessels of the microcirculatory bed. Dysfunction of the capillaries endothelium is manifested by a change of vasodilatation to vasospasm, as evidenced by morphometric changes in the diameter of the capillaries lumen in the experimental groups, and an increase in the permeability of the capillaries wall, which is confirmed by edema and disorganization of the connective tissue component.

Conclusions. Allergic inflammation leads to structural and functional reorganization of the metabolic link of the hemomicrocirculatory bed of guinea pig lungs, which has a multidirectional staging character depending on the duration of the experiment and is a manifestation of a violation of the compensatory-adaptive processes of hemomicrocirculation. The most pronounced changes in the form of a decrease in the diameter of the lumen of the blood capillaries of the lungs of guinea pigs by 23 % compared to the control are observed during the late period of the development of the allergic inflammatory process.

Key words: capillary, microcirculation, experimental allergic inflammation, lung, ovalbumin, guinea pig.

Current issues in pharmacy and medicine: science and practice 2021; 14 (1), 79–83

Морфологічна перебудова обмінної ланки мікроциркуляторного русла легень морських свинок після сенсibiliзації овальбуміном

С. С. Попко

Актуальною проблемою морфології та медицини, а також одним із недостатньо досліджених явищ у вивченні морфологічних змін під час хронічних алергічних захворювань дихальної системи залишається реакція мікросудин легень.

Мета роботи – вивчити морфологічні зміни судин обмінної ланки гемомікроциркуляторного русла легень морських свинок, сенсibiliзованих овальбуміном.

Матеріали та методи. За допомогою гістологічного, морфометричного методів вивчили легені 48 самців морської свинки в умовах експериментального овальбумін-індукованого алергічного запалення, яке моделювали шляхом триразової підшкірної сенсibiliзації та наступної 8-денної інтраназальної інгаляції овальбуміном. Для визначення структурної та функціональної перебудови кровоносних капілярів установлювали величину внутрішнього діаметра судин.

Результати. Встановили загальну закономірність реактивності мікроциркуляторного русла легень морських свинок при експериментальному овальбумін-індукованому алергічному запаленні, що полягає в суттєвій структурно-функціональній перебудові судин обмінної ланки мікроциркуляторного русла легень морської свинки. Так, виявили ознаки дисфункції ендотелію кровоносних капілярів: зміну дилатації судин на стійкий спазм, про що свідчили морфометричні зміни діаметра просвіту капілярів в експериментальних групах, а також збільшення проникності судинної стінки, що підтверджують набряк і дезорганізація сполучнотканинного компонента і строми.

ARTICLE INFO



<http://pharmed.zsmu.edu.ua/article/view/226851>

UDC 611.24.018:615.31:547.962.3].08

DOI: [10.14739/2409-2932.2021.1.226851](https://doi.org/10.14739/2409-2932.2021.1.226851)

Current issues in pharmacy and medicine: science and practice 2021; 14 (1), 79–83

Key words: capillary, microcirculation, experimental allergic inflammation, lung, ovalbumin, guinea pig.

*E-mail: kluchkosv@gmail.com

Received: 03.11.2020 // Revised: 20.11.2020 // Accepted: 25.11.2020

Висновки. Алергічне запалення призводить до структурної та функціональної реорганізації обмінної ланки мікроциркуляторного русла легень морських свинок, що має різноспрямований стадійний характер залежно від тривалості експерименту та є проявом порушення компенсаторно-адаптаційних процесів гемомікроциркуляції. Найбільше виражені зміни, а саме зменшення діаметра просвіту кровеносних капілярів легень морських свинок на 23 % порівняно з контролем виявили протягом пізнього періоду розвитку алергічного запального процесу.

Ключові слова: кровеносний капіляр, мікроциркуляція, експериментальне алергічне запалення, легень, овальбумін, морська свинка.

Актуальні питання фармацевтичної і медичної науки та практики. 2021. Т. 14, № 1(35). С. 79–83

Морфологическая перестройка обменного звена микроциркуляторного русла лёгких морских свинок после сенсibilизации овальбумином

С. С. Попко

Актуальной проблемой морфологии и медицины, а также одним из недостаточно исследованных явлений в изучении морфологических изменений при хронических аллергических заболеваниях дыхательной системы остается реакция микрососудов легких.

Цель работы – изучить морфологические изменения сосудов обменного звена микроциркуляторного русла легких морских свинок, сенсibilизированных овальбумином.

Материалы и методы. С помощью гистологического, морфометрического методов изучили легкие 48 самцов морской свинки в условиях экспериментального овальбумин-индуцированного аллергического воспаления, которое моделировали путем трехкратной подкожной сенсibilизации и последующей 8-дневной интраназальной ингаляции овальбумином. Для определения структурной и функциональной перестройки кровеносных капилляров определяли величину внутреннего диаметра сосудов.

Результаты. Установлена общая закономерность реактивности гемомікроциркуляторного русла легких морских свинок при экспериментальном овальбумин-индуцированном аллергическом воспалении, заключающаяся в существенной структурно-функциональной перестройке сосудов обменного звена микроциркуляторного русла легких морской свинки. Так, обнаружены признаки дисфункции эндотелия кровеносных капилляров: изменение дилатации сосудов на стойкий спазм, о чем свидетельствуют морфометрические изменения диаметра просвета капилляров в экспериментальных группах, а также увеличение проницаемости сосудистой стенки, что подтверждают отек и дезорганизация соединительнотканного компонента стромы.

Выводы. Аллергическое воспаление приводит к структурной и функциональной реорганизации обменного звена гемомікроциркуляторного русла легких морских свинок, которая носит разнонаправленный стадийный характер в зависимости от продолжительности эксперимента и является проявлением нарушения компенсаторно-адаптационных процессов гемомікроциркуляції. Наиболее выраженные изменения в виде уменьшения диаметра просвета кровеносных капилляров легких морских свинок на 23 % по сравнению с контролем отмечены в течение позднего периода развития аллергического воспалительного процесса.

Ключевые слова: кровеносный капилляр, микроциркуляція, экспериментальное аллергическое воспаление, легкое, овальбумин, морская свинка.

Актуальные вопросы фармацевтической и медицинской науки и практики. 2021. Т. 14, № 1(35). С. 79–83

In recent years, there has been an increase in the number of chronic respiratory allergic diseases which is a significant medical and social problem [1]. One of the insufficiently researched issues in the study of morphological changes in chronic respiratory allergic diseases is the reaction of pulmonary microvessels [2,3]. The metabolic link of the microcirculatory bed of lungs, located on the border between circulating blood and lung tissue, is one of the largest functionally active systems of the studied organ. The participation of blood capillaries in gas exchange, regulation of homeostatic and metabolic processes, and intercellular interactions, ensures the transport of gases, secretion of trophic and regulatory substances in normal conditions and during functional rearrangement aimed at adapting to damaging factors action at allergic inflammation [4]. Numerous studies have been devoted to the research of the processes of adaptive restructuring microvessels walls in human and animal lungs under the influence of various factors on the body [5–7]. However, structural rearrangement of microcirculatory bed of the lungs in allergic inflammation is still the subject of scientific discussions.

Aim

To study the morphological changes in the vessels of the metabolic link of the microcirculatory bed in the lungs of guinea pigs sensitized with ovalbumin.

Materials and methods

The object of the experimental study was lungs, removed from 48 sexually mature male guinea pigs weighing 450–600 g, which were kept in standard conditions of Zaporizhzhia State Medical University vivarium. All manipulations were carried out in compliance with the basic principles of work with experimental animals in accordance with the provisions of the European Convention for the Protection of Vertebrate Animals used for Experimental and Other Scientific Purposes (Strasbourg, 1986), the General Ethical Principles for Animal Experiments adopted by the First National Congress on Bioethics (Kyiv, 2001), the Law of Ukraine “On the protection of animals from cruelty” (from 21.02.2006).

Allergic airway inflammation was induced with subcutaneous sensitization and followed challenging with intranasal in-

halation with ovalbumin (OVA) (Sigma Aldrich, USA). Guinea pigs were actively sensitized with ovalbumin (0.5 mg/mL) with alum (10 mg/mL in saline) as an adjuvant (AlumVax Hydroxide vaccine adjuvant, OZ Biosciences France) subcutaneously injected into the interscapular region on days 0, 7 and 14. From days 21 to 28 of the experiment, guinea pigs were challenged for 15 min with inhalation of either OVA (10 mg/mL in saline) via a nebulizer (Little Doctor International, Singapore, LD-211C) attached to a plastic box. The animals were divided into 6 groups (8 animals in each). The first four groups are animals sensitized and aeroallergenic to OVA, withdrawn from the experiment, respectively, on the 23rd, 30th, 36th and 44th days after the start; group 5 is control group, where the animals received injections and were challenged with saline only; group 6 is intact one. For the purpose of rational presentation of the obtained data and their interpretation, we conditionally distinguish the early (23rd, 30th days of the experiment) and late (36th and 44th days after the start of the experiment) periods of the development of allergic inflammatory process in the lungs.

The animals were withdrawn from the experiment with an overdose of thiopental anesthesia (50 mg/kg) according to the established terms (23rd, 30th, 36th and 44th days of the experiment). Histological sections were stained with hematoxylin-eosin. Impregnation by silver was carried out according to the Laidlaw method to identify reticular and elastic fibers, and with Mason staining to assess the organization of collagen fibers. The sections were viewed and photographed with a compound binocular light microscope (Primo Star, Zeiss, Germany). The inner diameter of the blood capillaries was determined.

The research results were processed with modern statistical methods of analysis on a personal computer using the standard software package Microsoft Office 2010 (Microsoft Excel) and Statistica for Windows 13 (StatSoft Inc., № JP-Z804I382130ARCN10-J). While testing the hypothesis about the normal distribution of the studied parameters, we used the Shapiro–Wilk test and the Kolmogorov–Smirnov test of consistency. We used the Kolmogorov–Smirnov homogeneity criterion testing the hypothesis that two independent samples belong to the same distribution law. The arithmetic means (M) and standard errors of the mean ($\pm m$) were calculated. The statistical significance of intergroup differences according to the data obtained was established using the parametric Student's t-test (P^*) and the nonparametric U-Whitney–Mann test (P^{**}). The obtained indicators were compared between the median and interquartile range Me (Q1; Q3). Differences between the compared values at the level of 95 % ($P < 0.05$) were considered statistically significant.

Results

Histological analysis of microcirculatory bed of guinea pigs' lungs revealed the following components: arterioles and precapillaries demonstrated a resistive link, capillaries – an exchange link, postcapillary and muscle venules – a capacitive link. In animals of the intact group, capillaries of

the microcirculatory bed of lungs are thin-walled vessels of a continuous type with an average lumen diameter of $6.91 \pm 0.06 \mu\text{m}$, their wall consists of a continuous thin endothelium with a thickness of 0.1–0.2 μm and flattened pericytes.

The development of experimental ovalbumin-induced allergic inflammation in guinea pigs' lungs leads to structural and functional rearrangement of the lung microcirculatory bed, including its metabolic link. Histological examination revealed a regular sequence of morphological disorders manifestations in the system of lung microcirculation. It varies from the sludge phenomenon of erythrocytes and stasis of blood cells in the early period to hemorrhages and plasmorrhages of varying severity, accompanied by stromal connective tissue disintegration in the late period of development of experimental ovalbumin-induced allergic inflammation (*Fig. 1*).

Morphological changes in the structure of blood capillaries of pulmonary microcirculatory bed, identified at the light-optical level, have their own quantitative morphometric characteristics.

There were no statistically significant differences between the indices of the diameter of blood capillaries lumen in the animals of the intact and control groups ($P^* > 0.05$); this indicates that the procedure itself does not affect the changes in the morphometric parameters of the metabolic link of the microcirculatory bed of guinea pigs' lungs. There is a tendency for the blood capillaries lumen to increase in the diameter after sensitization and challenge with ovalbumin in the early period of development of experimental ovalbumin-induced allergic inflammation in the lungs. A statistically significant decrease in the diameter of the blood capillaries lumen, in comparison with the control group, is observed during the late period of development of allergic inflammation from the 36th day of observation (*Fig. 2*).

The average diameter of the blood capillaries lumen is $8.44 \pm 0.14 \mu\text{m}$ in the first experimental group on the 23rd day of observation, which is 6 % more than in the control group. Vasodilation is also preserved on the 30th day of observation in the second experimental group, where the average diameter of the blood capillaries lumen was $8.7 \pm 0.08 \mu\text{m}$, which was 9 % more than in the control group. In the late period of the development of allergic inflammation in guinea pigs' lungs, a statistically significant decrease in the diameter of the blood capillaries lumen by 7 % compared to the control was observed in the third experimental group on the 36th day of observation – $7.41 \pm 0.14 \mu\text{m}$ (*Fig. 2*). The tendency to a decrease in the parameters of the diameter the blood capillaries lumen persisted on the 44th day of observation in the fourth experimental group and was $6.15 \pm 0.15 \mu\text{m}$, which is 23 % less than in the control group ($P^{**} < 0.05$).

Discussion

Sensitization and challenge with intranasal inhalation with ovalbumin leads to a significant structural and functional restructuring of the metabolic link of the microcirculatory bed of guinea pigs' lungs. It is manifested with endothelial dysfunction of blood capillaries, consisting in changes from

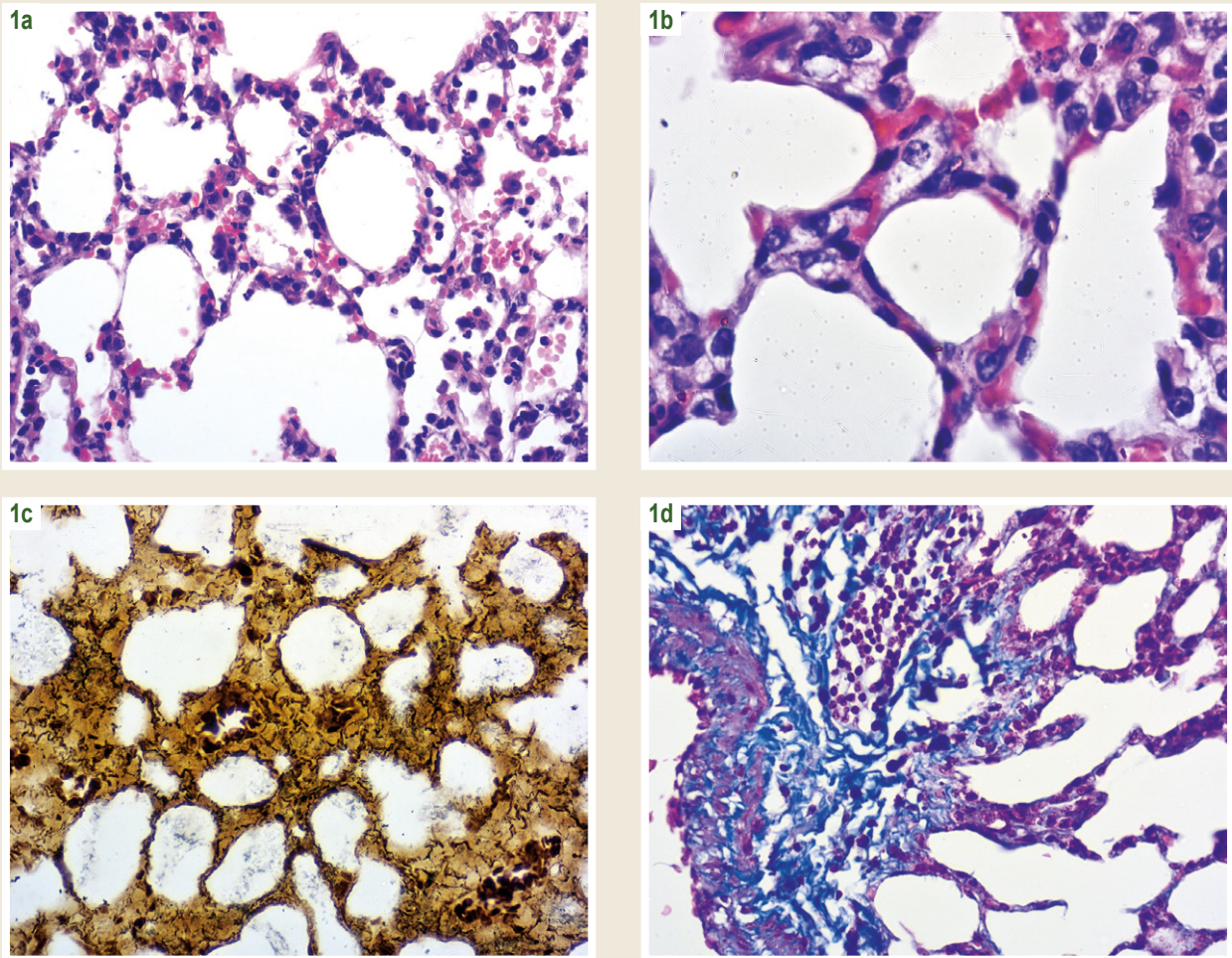


Fig. 1. Microscopic changes in the microcirculatory bed of guinea pigs' lungs after sensitization and challenge with ovalbumin on the 23rd (**1a**), 30th (**1b**), 36th (**1c**, **1d**) days after the start of experiment. **1a**, **1b**: vasodilation, plethora, hemorrhages, sludge-phenomenon of erythrocytes of capillaries of interalveolar septa; **1c**, **1d**: edema and disorganization of the fibrous elements of the connective tissue, surrounded microvessels. Staining: **1a**, **1b** – G. and E.; **1c** – Impregnation by silver according to Laidlaw; **1d** – Mason staining. $\times 400$, **1b** – $\times 1000$.

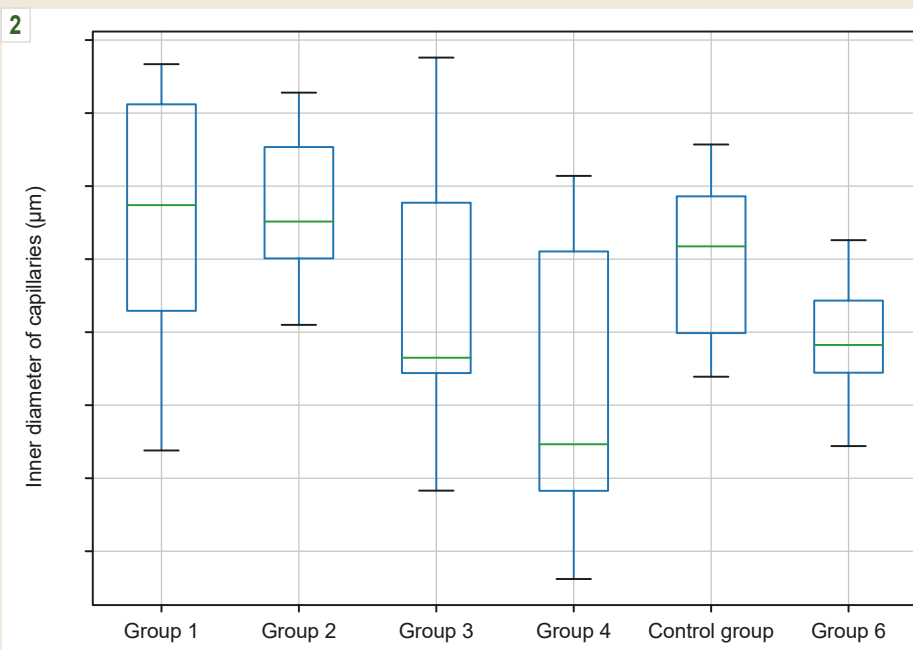


Fig. 2. Morphometric parameters of the blood capillaries of the microcirculatory bed of guinea pigs' lungs after sensitization with ovalbumin.

*: $P < 0.05$ (Student's t-test);
 **: $P < 0.05$ (Whitney–Mann U-test) comparing to the control group. Me (Q1; Q3).
 $M \pm m$ ($n = 8$).

vasodilatation in the early period of allergic inflammation to persistent spasm in the late period of inflammation. It is confirmed by morphometric changes in the diameter of the capillaries lumen in the experimental groups. Another change is increased permeability of the vascular wall, as evidenced by edema and disorganization of the stromal connective tissue component. A similar trend is observed in scientific research by other authors [8,9]. The degree of reaction of the microcirculatory bed vessels in the organs determines the dynamics of interstitial interaction during compensatory-adaptive and pathological processes. Adaptive changes in the microvessels of various organs are variable and staged, associated with phylo- and ontogenetic features and are manifested by regular compensatory reactions.

Allergic inflammation develops in guinea pigs' lungs as a result of sensitization and challenge with ovalbumin. The mechanism of inflammation is a cascade of processes involving a wide variety of cells, cytokines and mediators, whose interaction forms the characteristic inflammatory process and rearrangement of microvessels and bronchi [10]. The vascular factor plays an important role in the development of the allergic process in the lungs. Endothelial cells express P-selectin, E-selectin, Sox17, intercellular adhesion molecules-1 (ICAM-1) and blood cell adhesion molecules (VCAM-1) [11]. On the other hand, the components of the vascular wall (endothelium, smooth myocytes, fibroblasts) are targets for neuroendocrine [12] and immune factors [10] of the development of allergic process in the lungs.

Conclusions

1. Experimental ovalbumin-induced allergic inflammation leads to structural and functional reorganization of the exchange link of the microcirculatory bed of guinea pigs' lungs. It has multidirectional and staged nature, depending on the duration of the experiment and is a manifestation of a violation of the compensatory-adaptive processes of microcirculation.

2. The most pronounced changes such as a decrease in the diameter of the blood capillaries lumen of guinea pigs' lungs by 23 % compared to the control are observed during the late period of the development of the allergic inflammatory process.

Prospects for further research. We are going to study ultramicroscopical and immunohistochemical changes in microvessels of the lungs of guinea pigs with allergic inflammation.

Funding

This research is a part of the research work of Zaporizhzhia State Medical University "Immunomorphological characteristics of internal organs under the influence of endo and exogenous factors on the body", state registration № 0118U004250.

Conflicts of interest: author has no conflict of interest to declare.

Конфлікт інтересів: відсутній.

Information about author:

Popko S. S., MD, PhD, Associate Professor of the Department of Histology, Cytology and Embryology, Zaporizhzhia State Medical University, Ukraine.

ORCID ID: [0000-0002-5533-4556](https://orcid.org/0000-0002-5533-4556)

Відомості про автора:

Попко С. С., канд. мед. наук, доцент каф. гістології, цитології та ембріології, Запорізький державний медичний університет, Україна.

Сведения об авторе:

Попко С. С., канд. мед. наук, доцент каф. гистологии, цитологии и эмбриологии, Запорожский государственный медицинский университет, Украина.

References

- [1] Hrebniak, M. P., & Fedorchenko, R. A. (2019). Influence of industrial atmospheric pollution on the development of pathology of respiratory organs. *Pathologia*, 16(1), 81-86. <https://doi.org/10.14739/2310-1237.2019.1.166314>
- [2] Lu, S., Li, H., Gao, R., Gao, X., Xu, F., Wang, Q., Lu, G., Xia, D., & Zhou, J. (2015). IL-17A, But Not IL-17F, Is indispensable for airway vascular remodeling induced by exaggerated Th17 cell responses in prolonged ovalbumin-challenged mice. *The Journal of Immunology*, 194(8), 3557-3566. <https://doi.org/10.4049/jimmunol.1400829>
- [3] Hnatjuk, M. S., & Tatarchuk, L. V. (2018). Morphometric analysis remodeling vessels hemomicrocirculatory bed of jejunum at resections of liver. *Reports of Morphology*, 24(1), 16-20. [https://doi.org/10.31393/morphology-journal-2018-24\(1\)-03](https://doi.org/10.31393/morphology-journal-2018-24(1)-03)
- [4] Reichard, A., & Asosingh, K. (2019). Endothelial Cells in Asthma. In C. Pereira (Ed.), *Asthma – Biological Evidences*. IntechOpen. <https://www.intechopen.com/books/asthma-biological-evidences/endothelial-cells-in-asthma>
- [5] Pronina, O. M., Koptev, M. M., Bilash, S. M., & Yeroshenko, G. A. (2018). Response of hemomicrocirculatory bed of internal organs on various external factors exposure based on the morphological research data. *World of Medicine and Biology*, (1), 153-157.
- [6] Herasymuk, I. E., & Vatsyk, M. O. (2019). Features of remodeling of blood vessels of rat lungs in applying different methods of fluid resuscitation after general dehydration. *Bulletin of Problems Biology and Medicine*, (1, Part 2), 272-276. <https://doi.org/10.29254/2077-4214-2019-1-2-149-272-276>
- [7] Cai, Z., Liu, J., Bian, H., & Cai, J. (2019). Albigflorin alleviates ovalbumin (OVA)-induced pulmonary inflammation in asthmatic mice. *American journal of translational research*, 11(12), 7300-7309.
- [8] Zemmouri, H., Sekiou, O., Ammar, S., El Feki, A., Bouaziz, M., Messarah, M., & Boumendjel, A. (2017). Urtica dioica attenuates ovalbumin-induced inflammation and lipid peroxidation of lung tissues in rat asthma model. *Pharmaceutical Biology*, 55(1), 1561-1568. <https://doi.org/10.1080/13880209.2017.1310905>
- [9] Antwi, A. O., Obiri, D. D., & Osafo, N. (2017). Stigmasterol modulates allergic airway inflammation in guinea pig model of ovalbumin-induced asthma. *Mediators of Inflammation*, 2017, 2953930. <https://doi.org/10.1155/2017/2953930>
- [10] Lambrecht, B. N., & Hammad, H. (2014). The immunology of asthma. *Nature Immunology*, 16(1), 45-56. <https://doi.org/10.1038/ni.3049>
- [11] Ha, E. H., Choi, J.-P., Kwon, H.-S., Park, H. J., Lah, S. J., Moon, K.-A., Lee, S.-H., Kim, I., & Cho, Y. S. (2019). Endothelial Sox17 promotes allergic airway inflammation. *Journal of Allergy and Clinical Immunology*, 144(2), 561-573. <https://doi.org/10.1016/j.jaci.2019.02.034>
- [12] Popko, S. S., Yevtushenko, V. M., & Syrtsov, V. K. (2020). Influence of pulmonary neuroendocrine cells on lung homeostasis. *Zaporozhye Medical Journal*, 22(4), 568-575. <https://doi.org/10.14739/2310-1210.2020.4.208411>